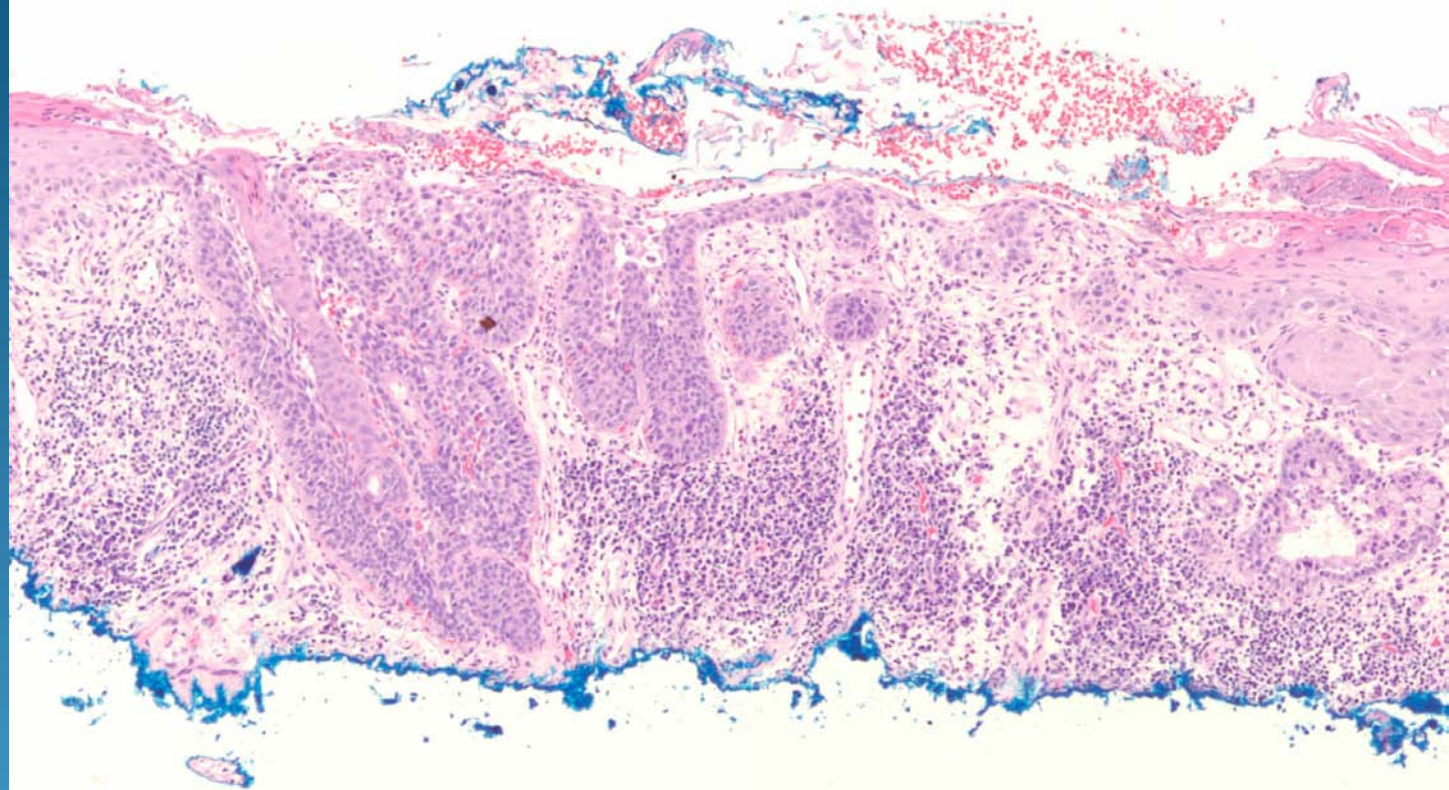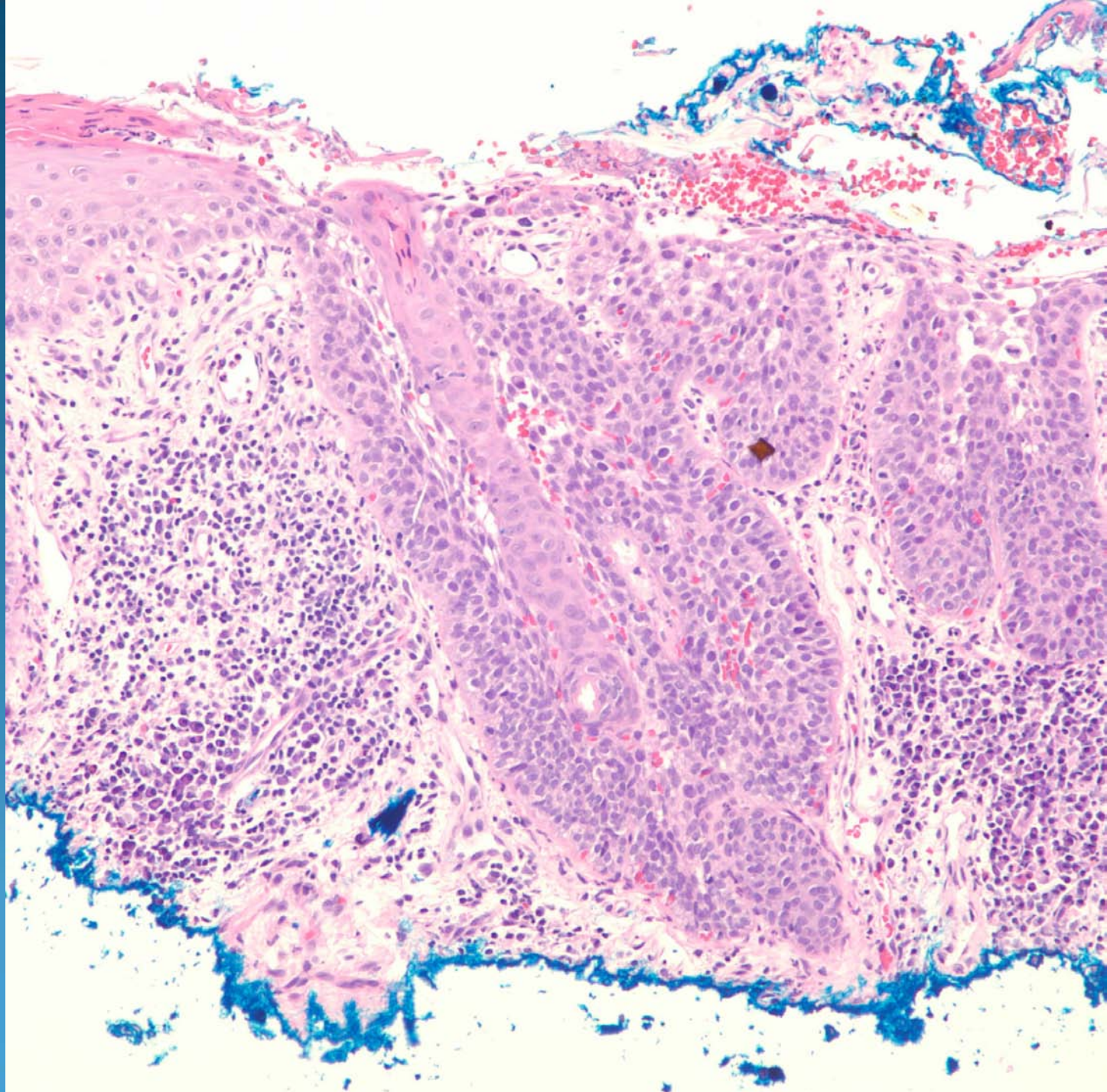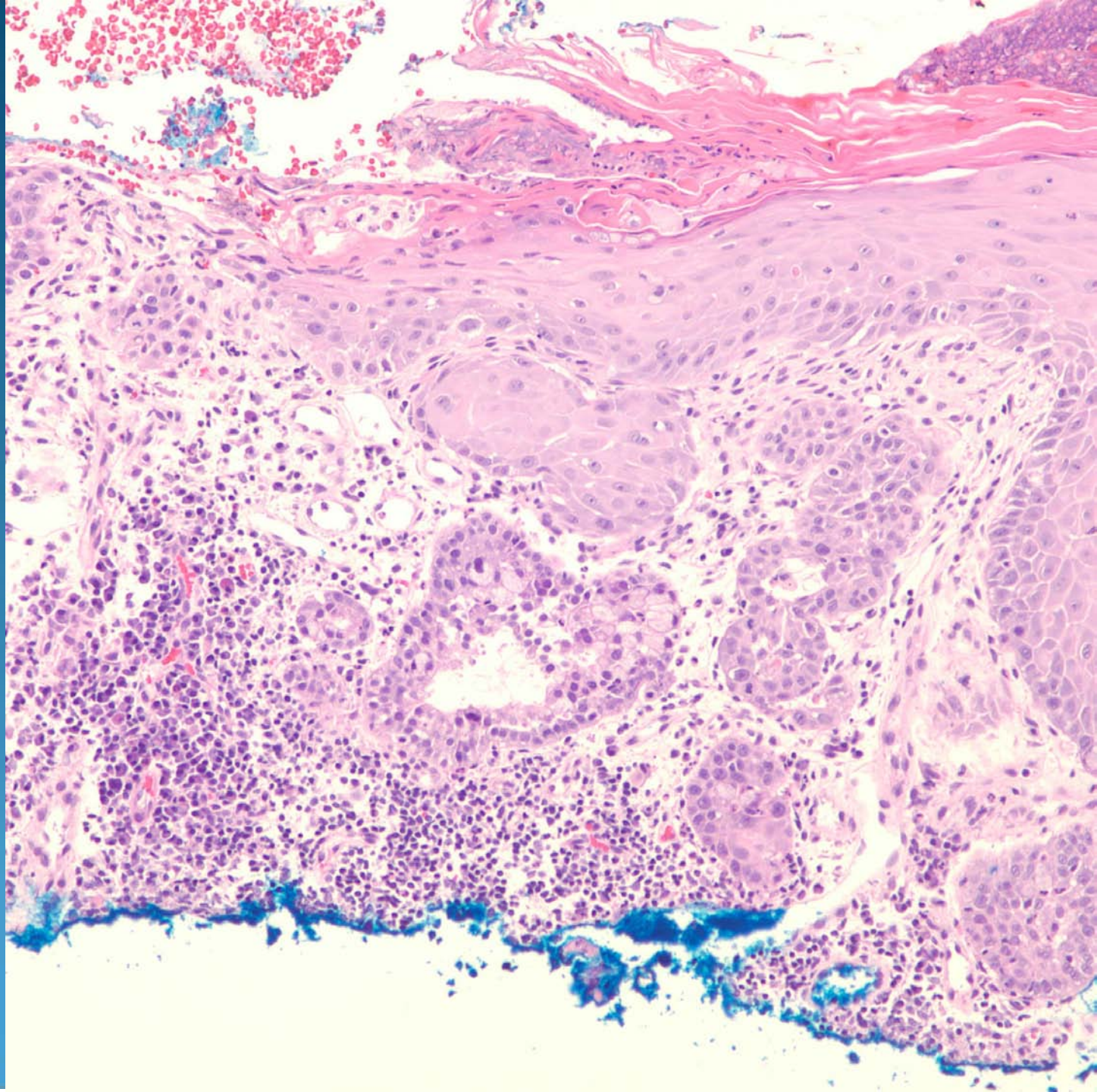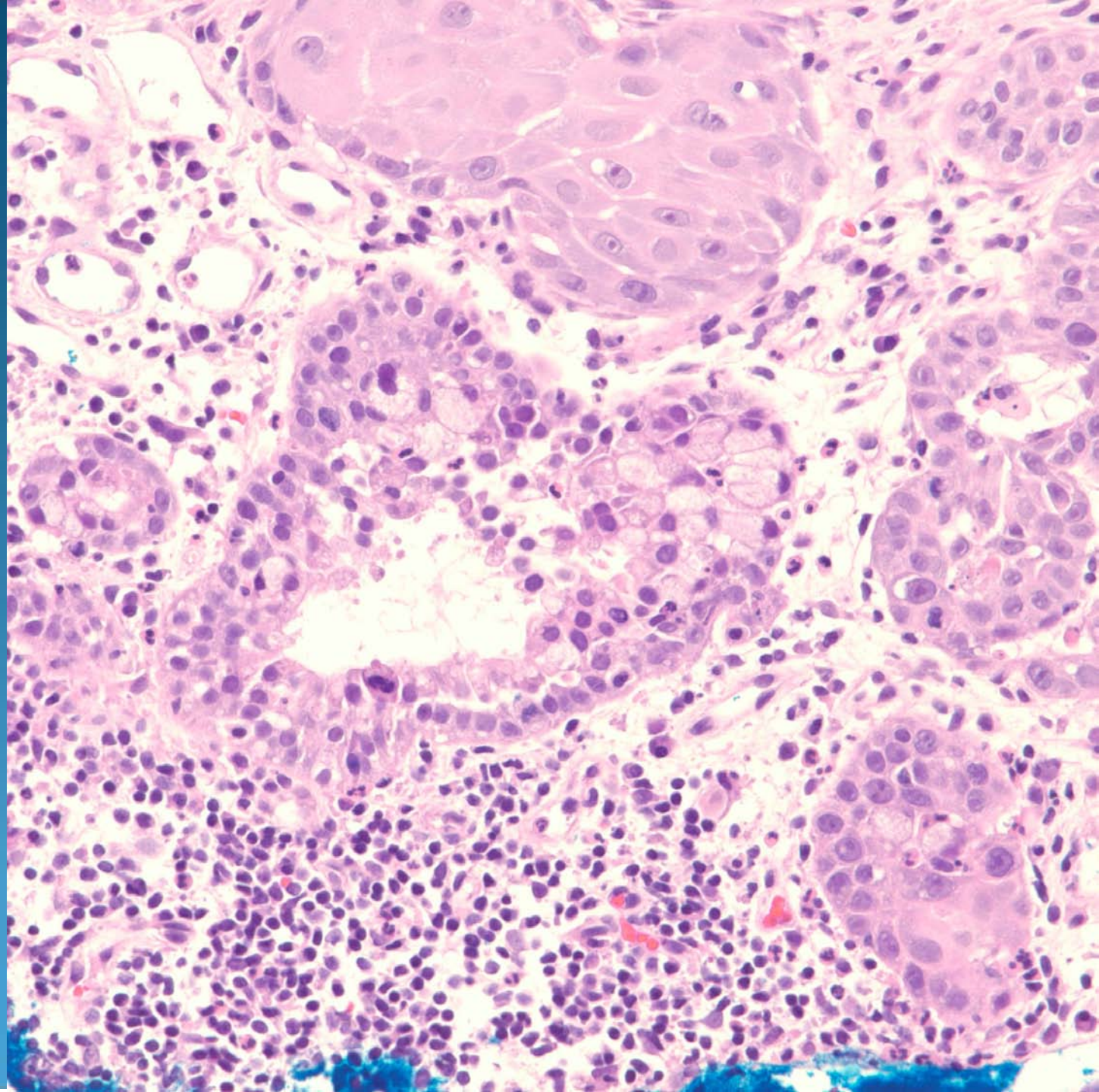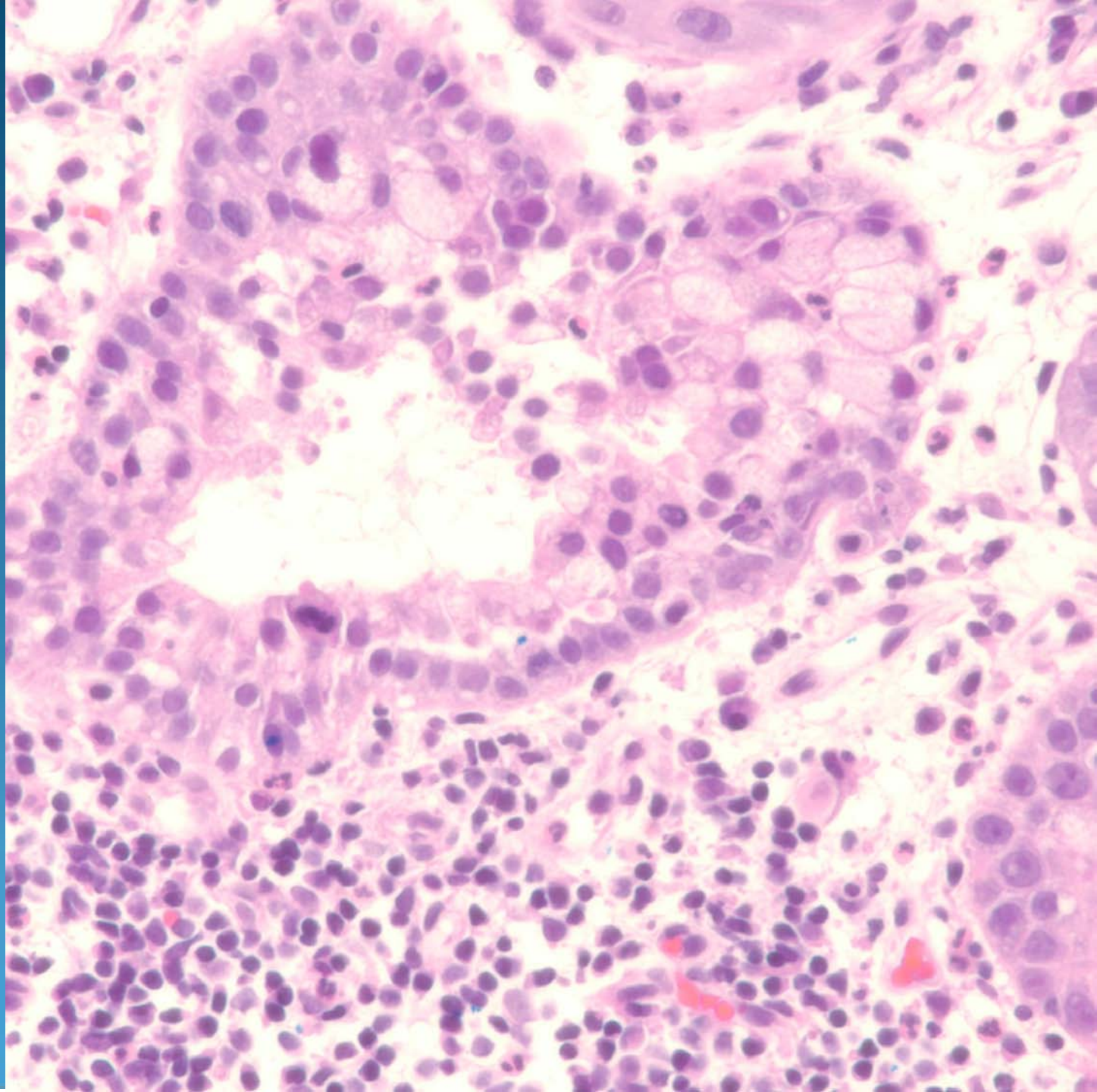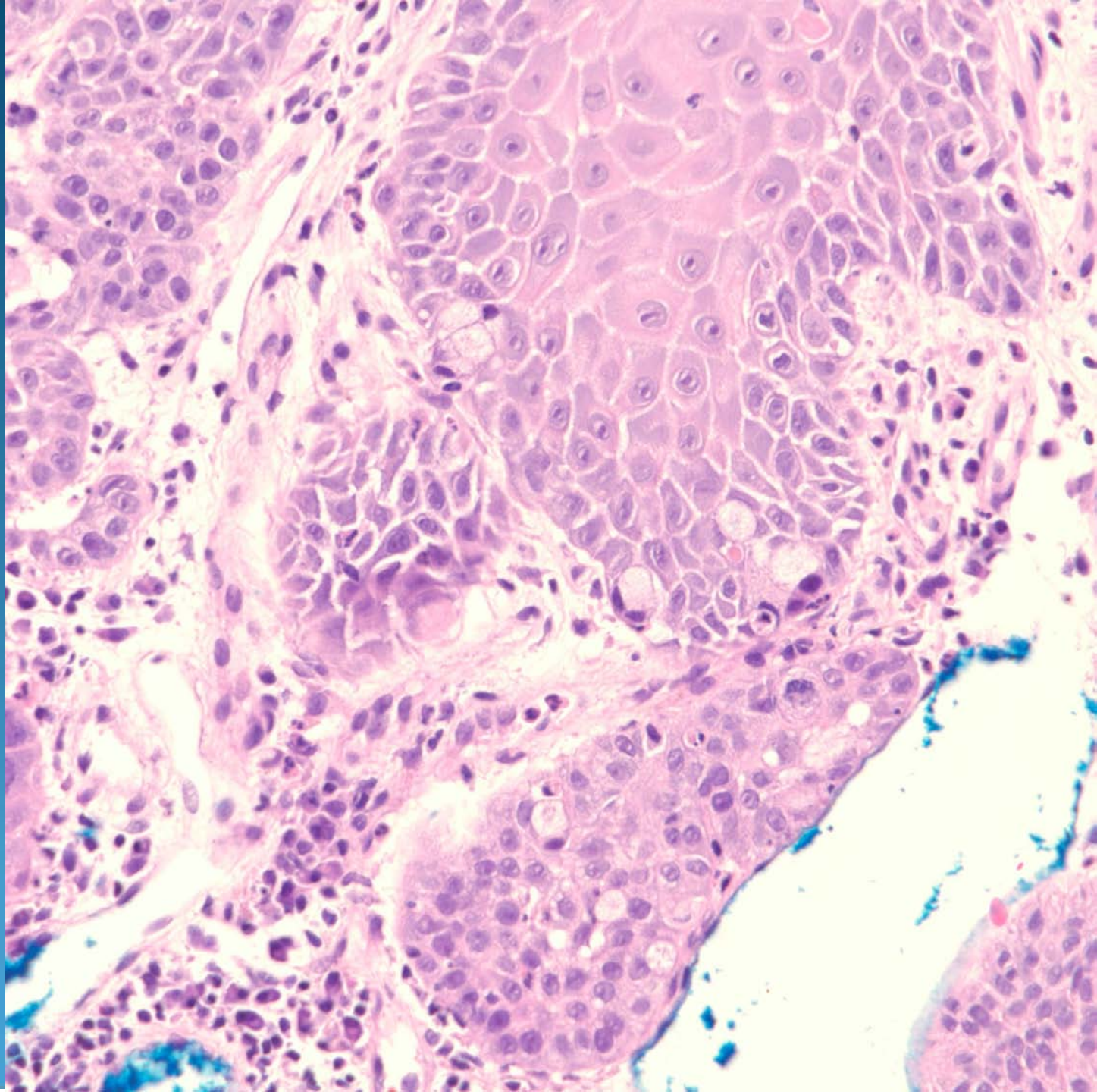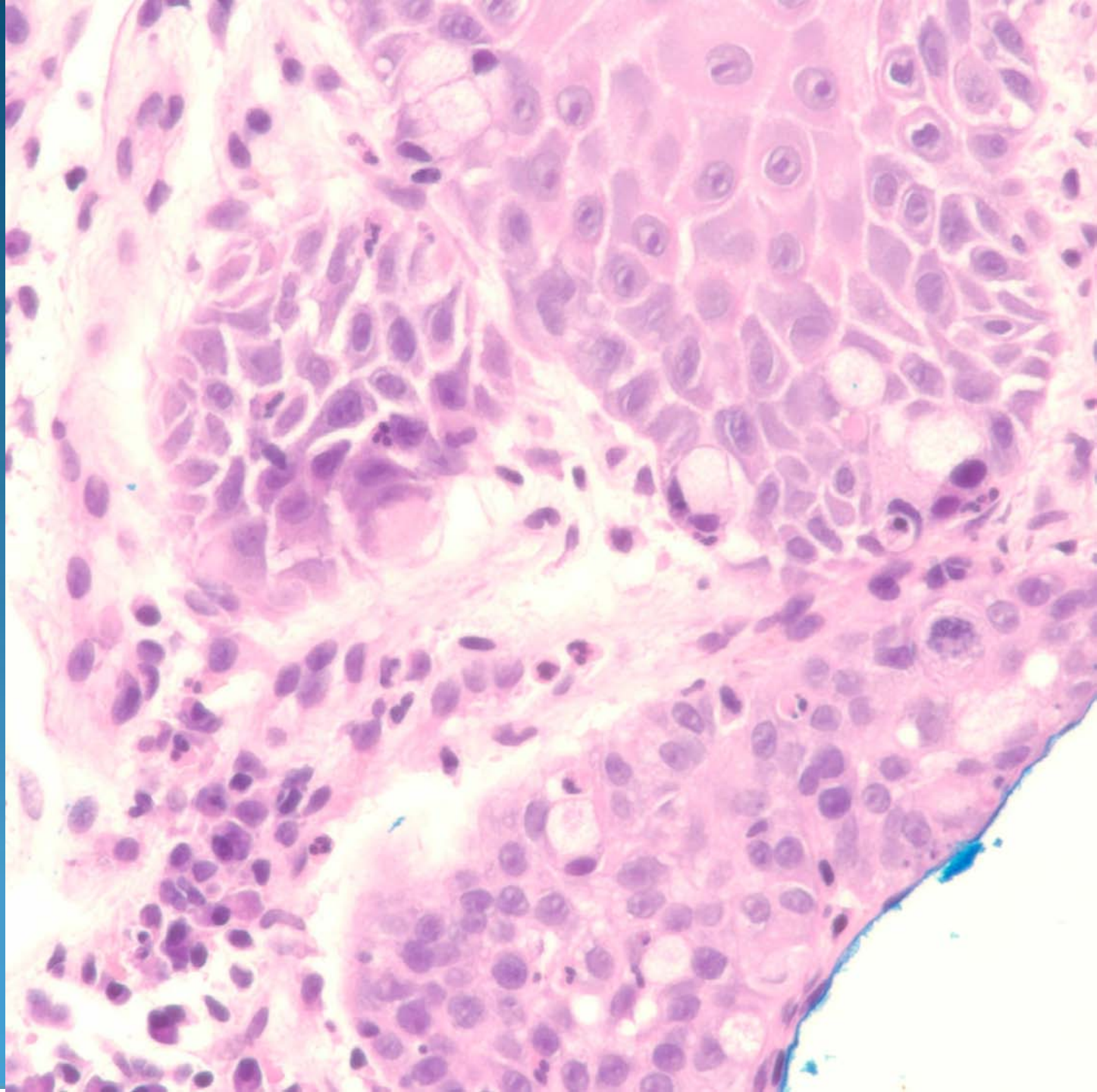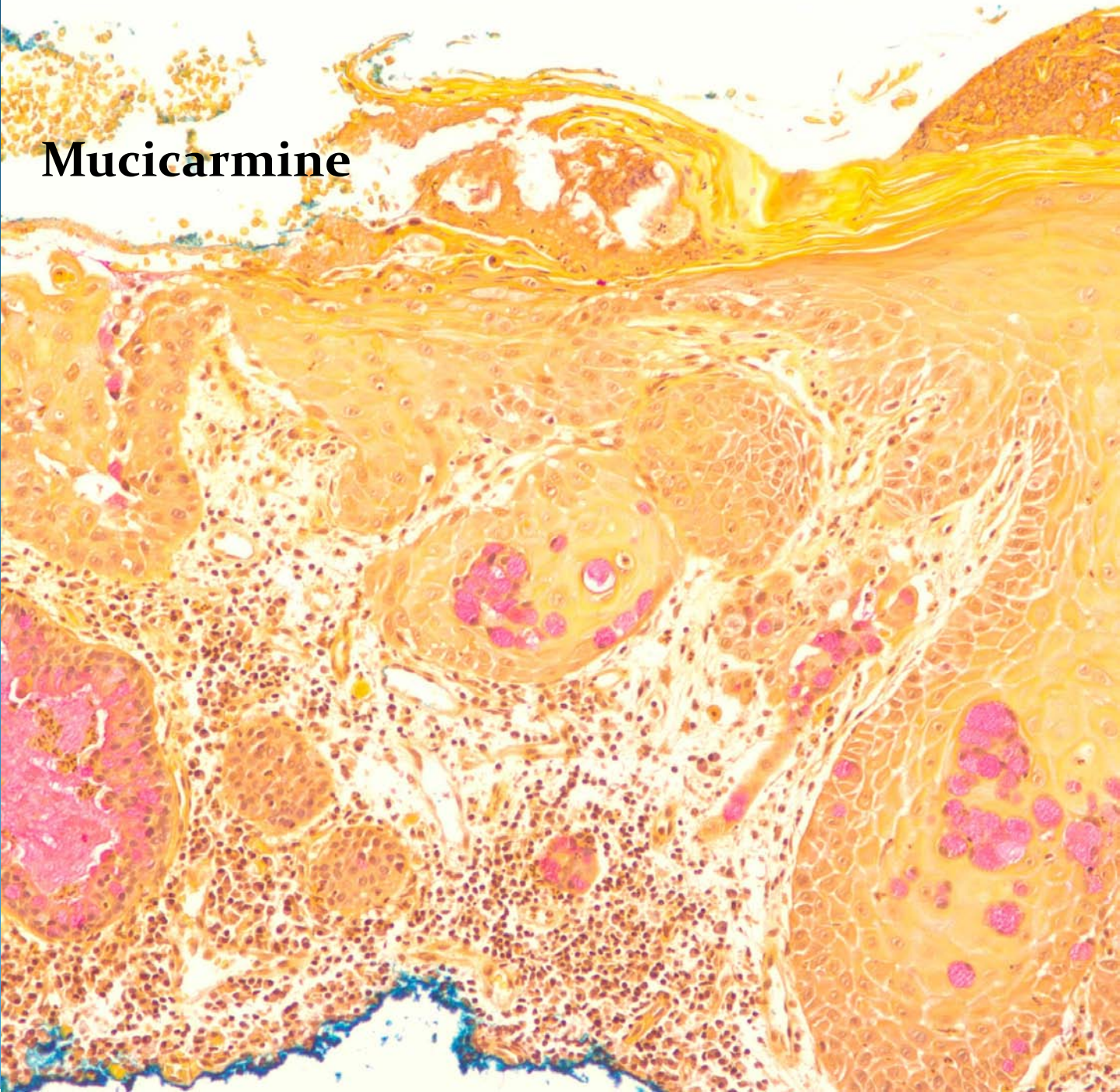
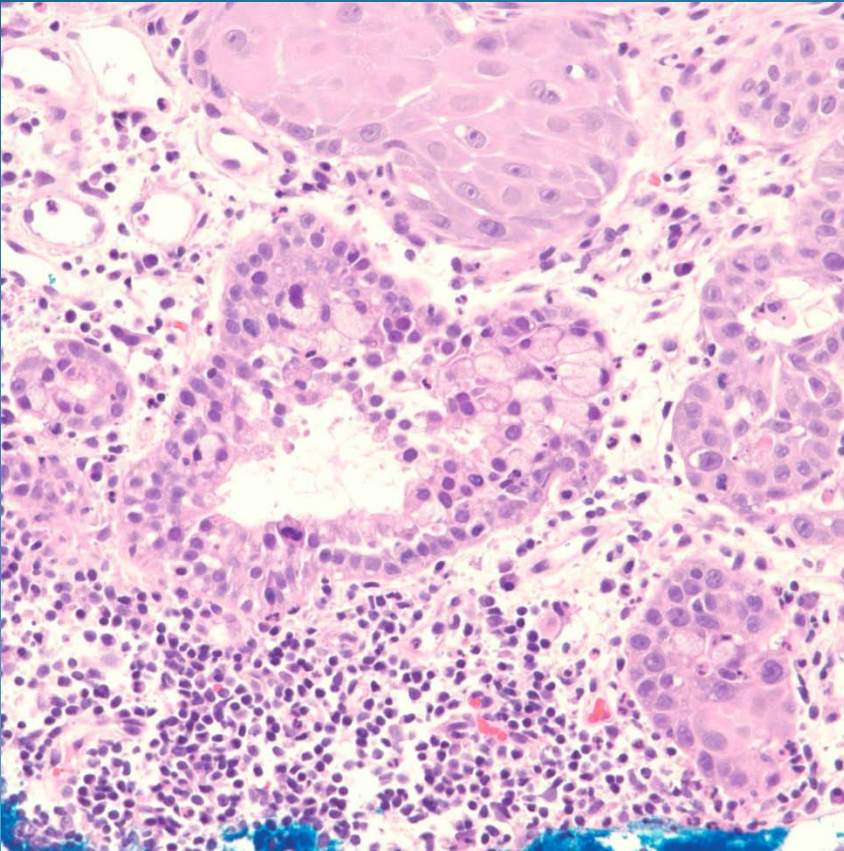


Mucicarmine



Squamous Cell Carcinoma with Mucinous Differentiation

Pearls



- Conventional squamous cell carcinoma
- Look for glandular or signet ring cells
- Confirm by mucin stains
- Rule out collision tumor, metastatic signet ring adenocarcinoma